



Enhanced Oral Assessment

VELscope Vx Step-By-Step Examination Guide

Note: This is an abbreviated clinical guide. Please see the VELscope Vx Training DVD for more detailed information.

- 1 Review the patient's relevant medical and dental history.
- 2 Conduct a thorough extra-oral and intra-oral examination both visually and manually, palpating all the structures of the head and neck.
- 3 Repeat the intra-oral examination using the VELscope Vx by viewing the oral cavity through the VELscope Handpiece (Figure 1). Maintain a distance of approximately 2 inches (5 cm) from the oral cavity to optimize the visualization of the natural tissue fluorescence.
- 4 Abnormal tissue typically appears as an irregular, dark area that stands out against the otherwise normal, green fluorescence pattern of surrounding healthy tissue.
- 5 If a suspicious area is discovered, reevaluate under white light and VELscope trying to identify what might have caused the region to appear abnormal. Take into consideration its appearance under both VELscope and white light, its response to palpation, and salient patient history information.
- 6 Photo-document any areas of concern both under white light and through the VELscope Vx.
- 7 Record all relevant findings. Documentation forms are available at www.velscope.com.
- 8 Inform the patient of all relevant findings and the appropriate course of action.
- 9 Follow up or refer as appropriate.

VELscope Vx Step-By-Step Examination Guide

Fluorescence Visualization in the “Normal” Mouth

- Understand what a normal oral cavity looks like under VELscope to best appreciate what may be abnormal.
 - The attached gingiva and anterior tonsillar pillars, for example, often have a naturally darker appearance.
 - Pigmented tissue appearing dark under white light usually also looks dark under VELscope Vx.
- Inflammation typically appears darker under VELscope due to the excess blood content.
- The oral cavity is naturally exposed to varying degrees of chronic irritation and mild inflammation.
 - Due to inflammation, the buccal mucosa, lateral surfaces of the tongue and hard palate may sometimes show darker areas typically characterized by poorly-defined borders.
- Hyperkeratosis may often appear bright under VELscope because of strong keratin fluorescence.

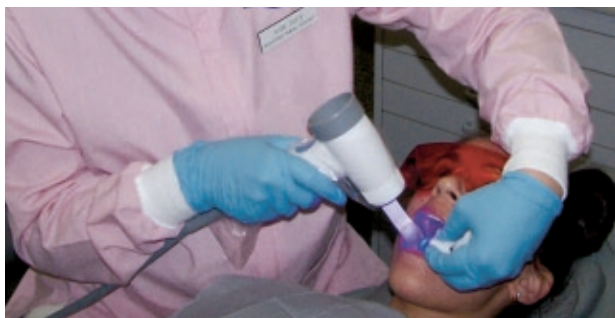

Figure 1. VELscope Vx examination: The clinician shines the blue excitation light into the patient’s oral cavity and looks through the VELscope Handpiece

Characteristics that Increase Suspicion of Dysplasia and/or Oral Cancer

- Highly darkened appearance—strong loss of fluorescence
- High-risk location (e.g., lateral/ventral tongue)
- Unilateral presentation
- Asymmetry and/or irregular shape
- Extension over more than one kind of oral structure

Blanching

- Observe the suspicious, typically darker, area through the VELscope Handpiece while applying a light amount of pressure with the back side of an explorer or similar instrument in a sweeping motion to diffuse any blood from the area.
- If the normal green fluorescence returns with this pressure, then the lesion may have an inflammatory component.
- For some important considerations when interpreting the effects of blanching, see the VELscope Vx Training DVD.

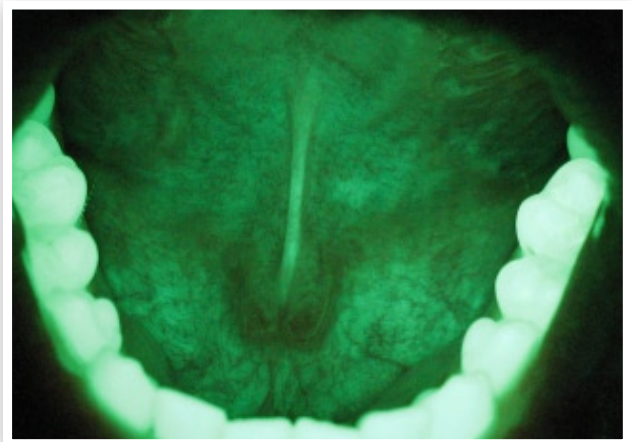
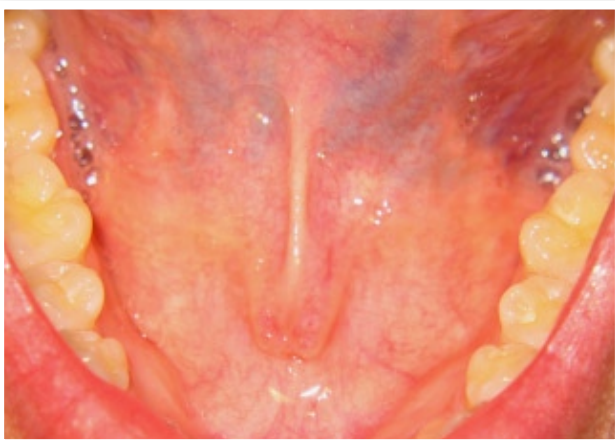Follow-up

- If a suspicious area cannot be ruled out as benign, it is usually appropriate to perform a follow-up examination (typically in 2 weeks).
- At this time, evaluate whether the suspicious area has changed, especially if the presumed causative agent has been removed.
- If the suspicious area has not cleared up after this follow-up time, use your clinical judgement and proceed with further investigation according to the regular standard of care (e.g. referral to a specialist, etc.)

Surgical Biopsy – The Gold Standard

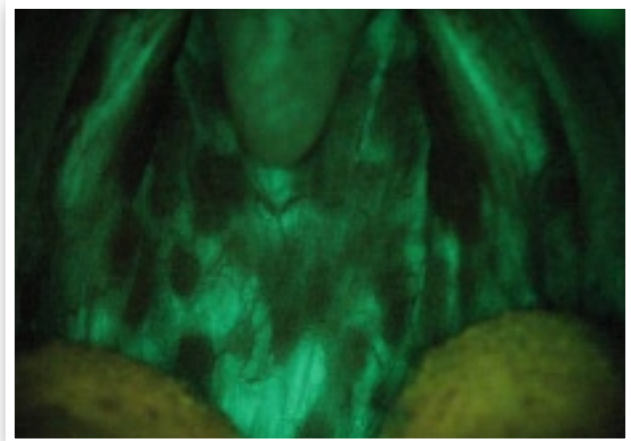
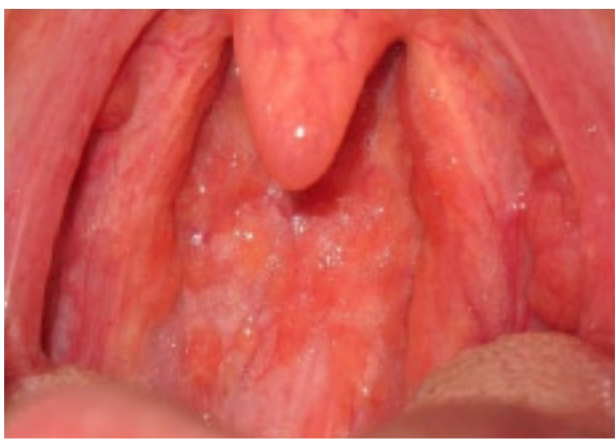- Remember: the gold standard for diagnosing precancerous and cancerous lesions in the soft tissues of the oral cavity is surgical biopsy.
- A biopsy showing dysplasia is NOT a “false positive”; discovering lesions early in the disease development process allows for the highest probability of a favourable treatment outcome.

Figure 2. Representative examples of the appearance of healthy vs. suspicious oral tissue under both incandescent light and VELscope examination.



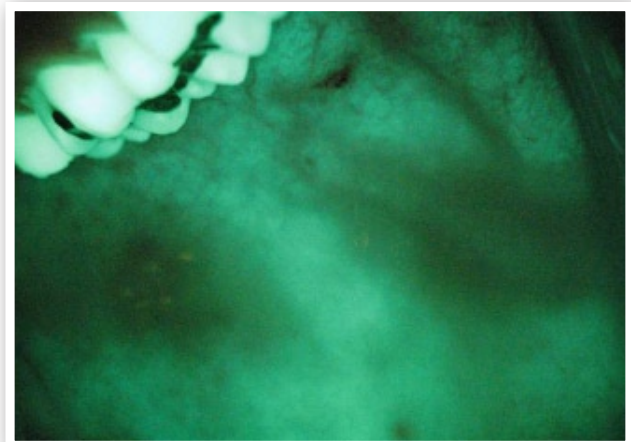
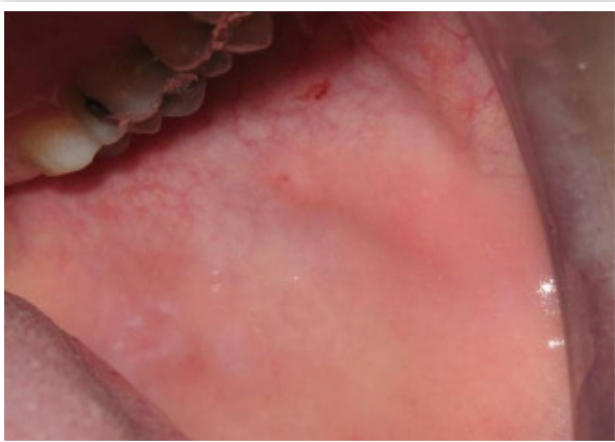Normal Floor of the Mouth

Sometimes the area around the sub-lingual gland can be well vascularized, and can lead to a variable degree of loss of fluorescence.



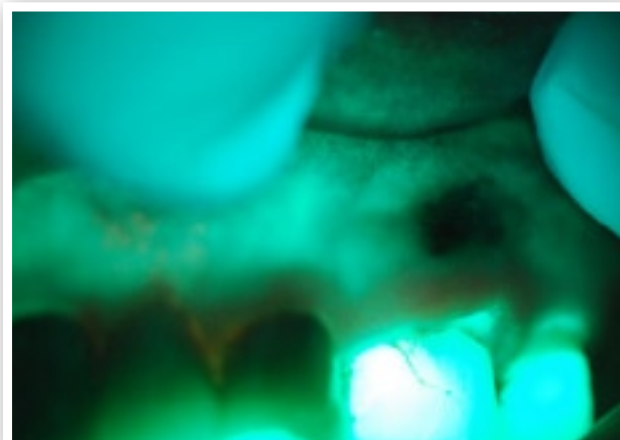
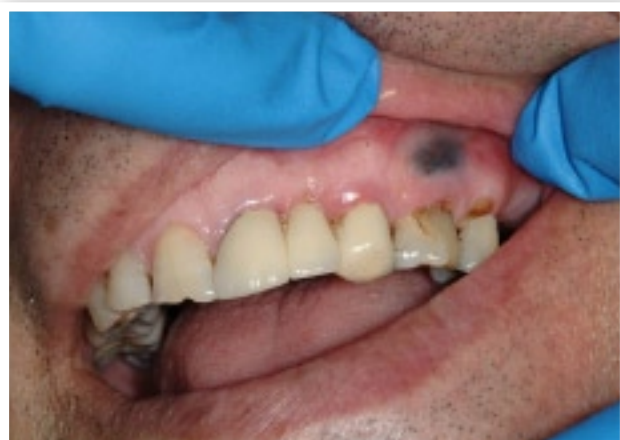Normal Variation - Oropharynx with Numerous Lymphoid Aggregates

Sometimes the oropharynx can host varying numbers of lymphoid aggregates, which, due to tissue structure, display a pronounced loss of fluorescence.



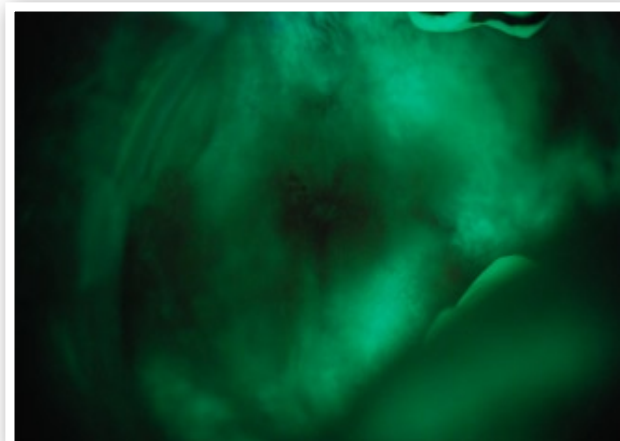
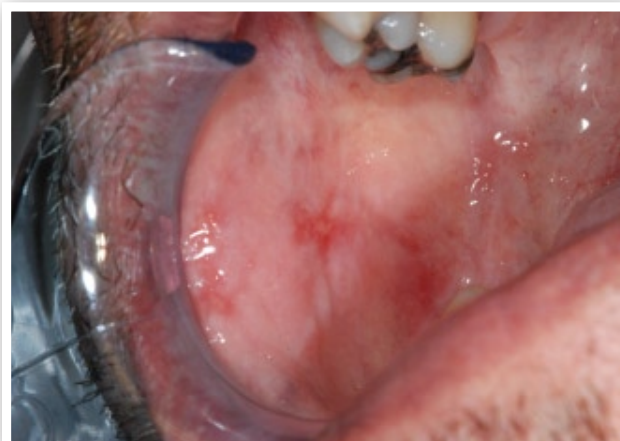Irritation and Inflammation

The buccal mucosa is a common site for irritation and consequent inflammation; inflammation always shows a distinct loss of fluorescence because of increased blood content.



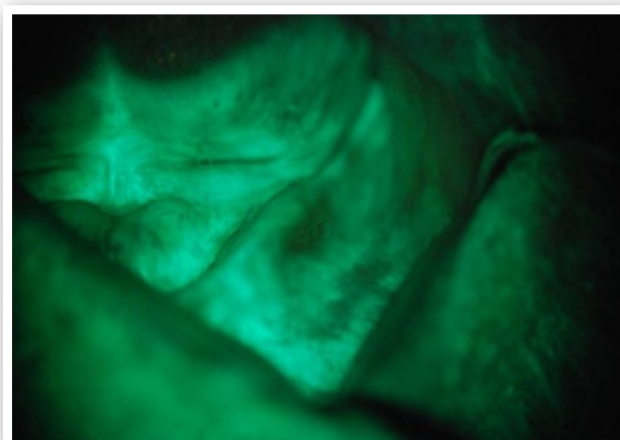
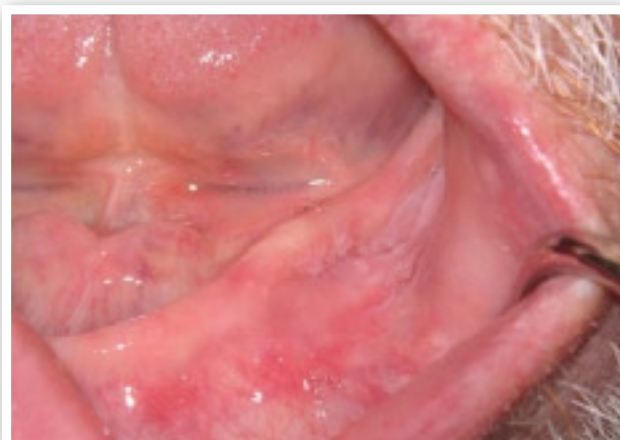Pigmented Lesions: Amalgam Tattoo

Pigmented lesions show a loss of fluorescence for the same reason that they appear pigmented under white light: absorption of light by the pigment. One should expect the size and shape of the loss of fluorescence to be the same as the size and shape of the pigmented area under white light.



Erosive Lichen Planus

The intense inflammation associated with erosive lichen planus results in a pronounced loss of fluorescence.



Dysplasia

The hyperkeratotic area on the ridge is in fact dysplasia, and shows a strong loss of fluorescence.

For more information, contact your dealer or visit www.velscope.com
Images courtesy of the British Columbia Oral Cancer Prevention Program



Enhanced Oral Assessment